

# Does the 'Gull-Sign' in Acetabular Fractures Really Indicate a Dome Impaction?

Egli RJ<sup>1</sup>, Rosenstock P<sup>1</sup>, Ivanova S<sup>2</sup>, Keel MJB<sup>2</sup>, Bastian JD<sup>2</sup>

<sup>1</sup> Department of Diagnostic, Interventional and Pediatric Radiology, Inselspital, Bern University Hospital, 3010 Bern, Switzerland

<sup>2</sup> Department of Orthopaedic Surgery and Traumatology, Inselspital, Bern University Hospital, 3010 Bern, Switzerland

## Background

The presence of the so-called "Gull-Sign" on conventional pelvic radiographs in cases of acetabular fractures was described about 20 years ago as a correlate of superomedial dome impaction. Patients with osteopenia exhibiting this sign did not benefit from open reduction and internal fixation (ORIF). Since then, the "Gull-Sign" has been used in the decision-making process for the surgical management of geriatric acetabular fractures.

## Purpose

The aim of this study was to determine, using pelvic CT scans, the extent to which a "Gull-Sign" on radiographs actually corresponds to a dome impaction seen on CT.

## Methods

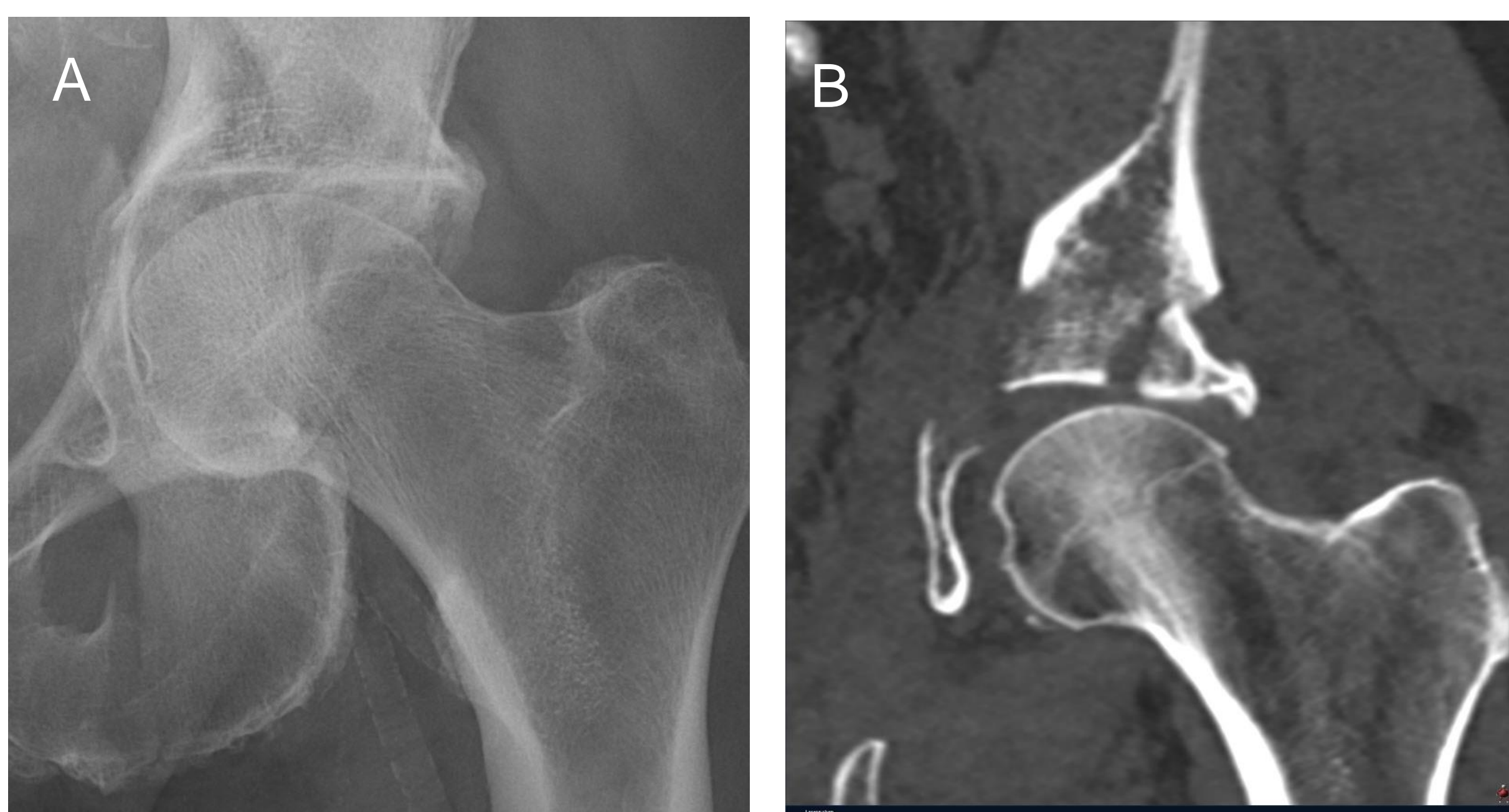This retrospective study included conventional radiographs and CT scans of 207 acetabular fractures over a 10-year period (patient age  $70 \pm 17$  years, 76% male). The presence of a "Gull-Sign" was analyzed on the pelvic overview radiographs, and the presence of dome fragments was assessed on the CT scans.

## Results

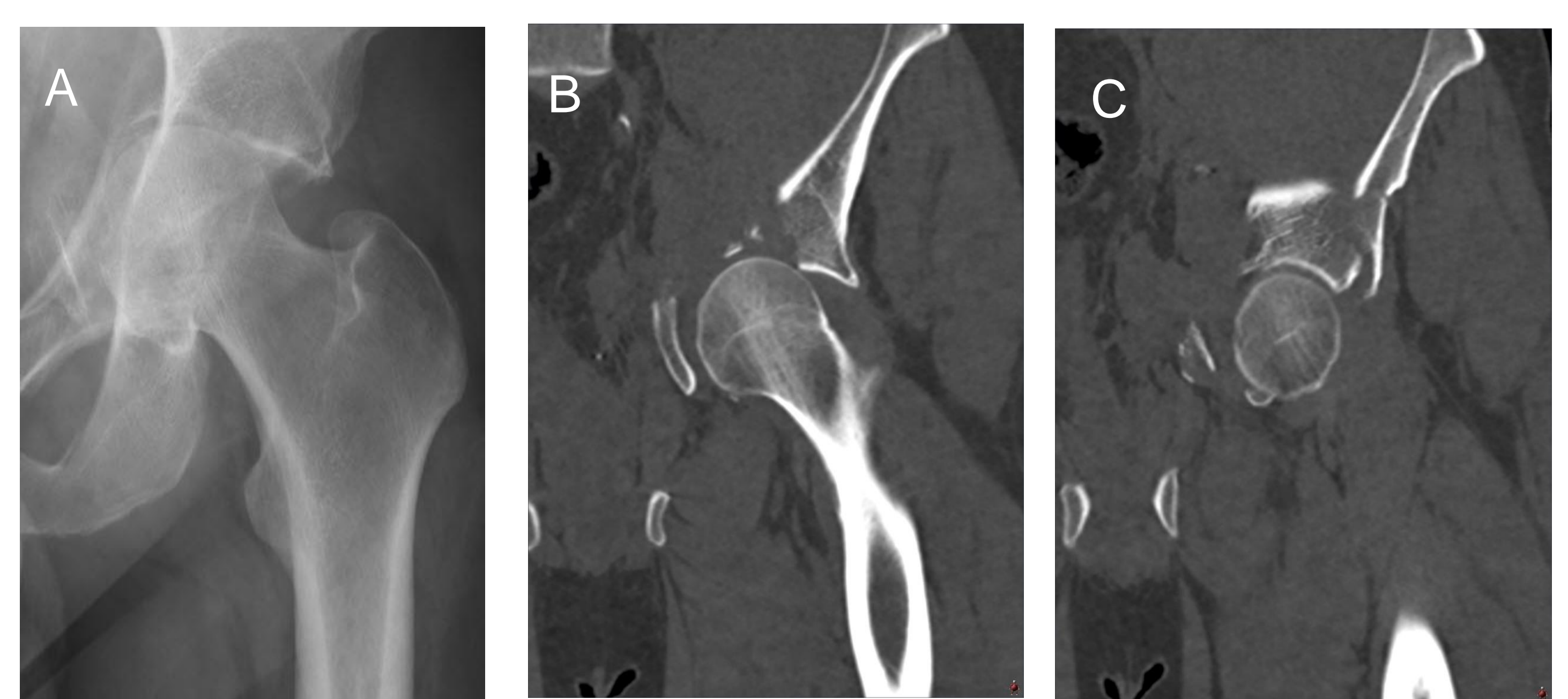
The "Gull-Sign" was present on pelvic radiographs in 51 out of 207 cases (25%). Of these, 29 (57%) showed an impacted dome fragment located superomedially on CT. In the remaining 22 cases (43%), CT revealed that fractures through the dome presented as false-positive "Gull-Signs" on radiographs due to spatial superimposition: the protruding fracture fragment of the dome was attached to the anterior column of the acetabulum in 15 out of 22 cases (68%), to the posterior column in 5 out of 22 cases (23%), and to the quadrilateral surface in 2 out of 22 cases (10%). In 45 out of 156 cases (29%) with a negative "Gull-Sign", impacted dome fragments were found on CT, with 39 (87%) located posteromedially and 6 (13%) superomedially.

		Dom Impaction	
		Yes	No
Gull-Sign	Yes	29	22
	No	45	111

**Table 1** Correlation of the "Gull-sign" with a dome impaction in CT



**Figure 1** "Gull-sign" in the X-ray and the correlating impacted superomedial dome fragment in the CT.



**Figure 2 (A)** "Pseudo-Gull-sign" in the X-ray as a result of a superimposed projection of the (B) lateral acetabulum with a (C) joint-bearing fragment in connection with the acetabular anterior pillar.

## Conclusion

The "Gull-Sign" on pelvic overview radiographs has a sensitivity of only 39% and a specificity of 83% for impacted dome fragments. Pelvic radiographs can only detect dome impactions located superiorly in the acetabulum due to projection, and fail to detect posterior dome fragments (53% of cases). The positive predictive value of the "Gull-Sign" is only 56%. Due to overlay effects on pelvic radiographs, acetabular fractures without dome impactions can present with a positive "Gull-Sign", which should thus be considered a "Pseudo-Gull-Sign."

The "Gull-Sign" on pelvic radiographs must be correlated with a CT scan to make an appropriate decision regarding whether ORIF or a primary total hip arthroplasty is the treatment of choice.